PhotoFix® | Decellularized Bovine Pericardium

Published Literature



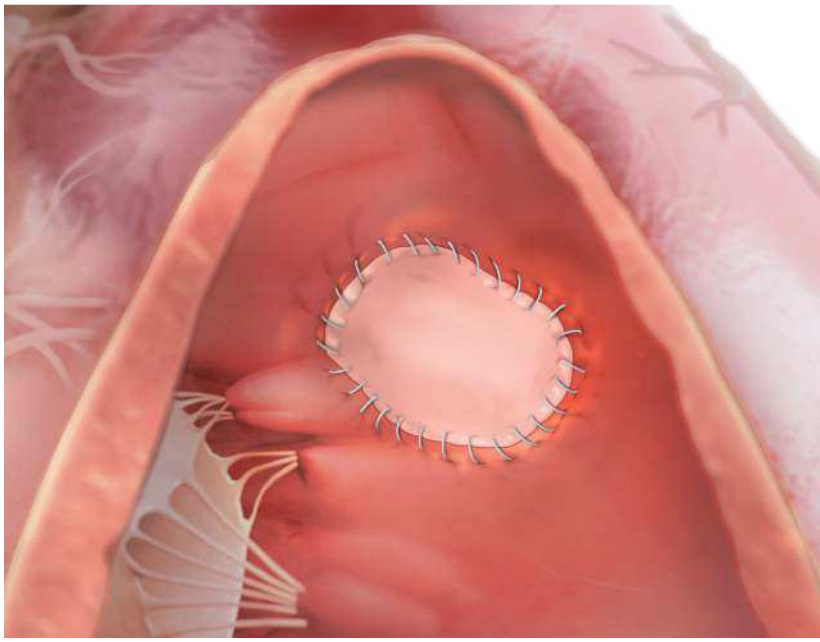

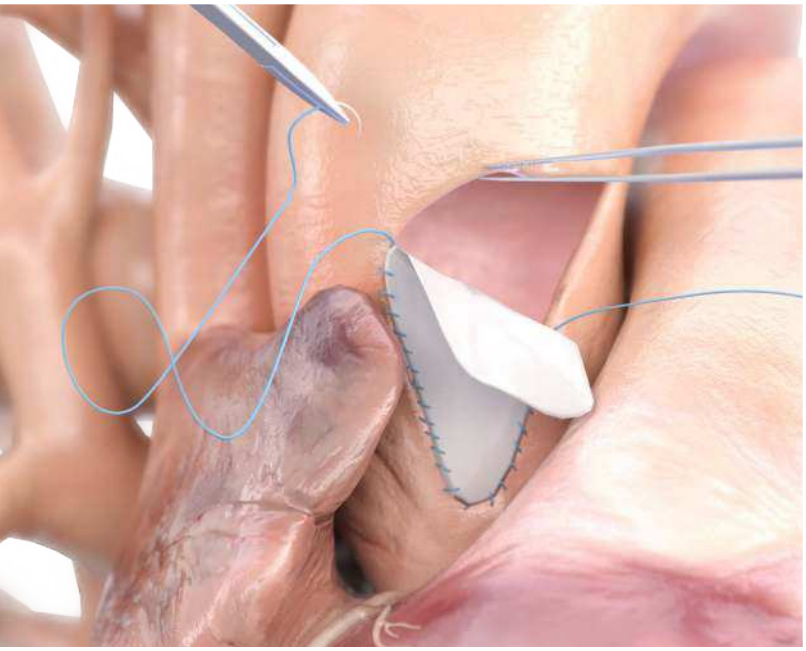

CryoLife®
Life Restoring Technologies®

Clinical Publications

1. Baird CW, Myers PO, Piekarski B, Borisuk M, Majeed A, Emani SM, Sanders SP, Nathan M, Del Nido PJ. Photo-oxidized bovine pericardium in congenital cardiac surgery: single-centre experience. Interact Cardiovasc Thorac Surg. 2017; 24(2): 240-244. PubMed link

   "Objectives: Dye-mediated photo-oxidation of pericardium is an alternative method to chemical treatment with glutaraldehyde for cross-linking collagen, providing biostability of the patch material while avoiding late calcification and cytotoxicity. There are few data available, on using photo-oxidation-treated pericardium, in congenital cardiac surgery. This study reports the outcomes using Photofix™ bovine pericardium in neonates, infants, children and young adults undergoing paediatric cardiac surgery.

   Methods: A total of 490 patches in 383 consecutive operations (364 patients) were used in the surgical repair of congenital heart defects at our institution from October 2008 to October 2011. Recorded variables included demographic data, age at operation, primary cardiac diagnosis, associated complications and number, type and location of patches placed and patch-related reintervention.

   Results: Median age at operation was 5.3 years, ranging from <1 month to 56 years. The overall survival rate at late follow-up was 92%, and no deaths were related to failure of the tissue substitute. Two patients (0.5%) underwent reintervention late due to patch material failure: one for residual shunt after Rastelli repair and one for aneurysmal dilatation of a right ventricular outflow tract patch. The patch material was explanted in 8 patients at a mean of 20 months (range, 1–72 months) following implantation. Histological examination revealed mild to moderate inflammation with variable calcification.

   Conclusions: Photo-oxidized bovine pericardium demonstrated excellent performance when used as a patch material in cardiovascular repair in children. Its handling characteristics and biocompatibility are consistent with a wide range of applications."

2. Majeed A, Baird C, Borisuk MJ, Sanders SP, Padera RF Jr. Histology of Pericardial Tissue Substitutes Used in Congenital Heart Surgery. Pediatr Dev Pathol. 2016; 19(5): 383-388. PubMed link

   "Pericardium is used as a tissue substitute during pediatric heart surgery. However, little is known about the histological characteristics of pericardial tissue substitutes. We searched our clinical and Pathology databases to identify cases in which glutaraldehyde-preserved autologous pericardium, PhotoFix bovine pericardium, or Peri-Guard Repair Patch glutaraldehyde-preserved bovine pericardium was used as patch material during cardiac surgery and in which explanted tissue substitute was available for histologic examination. Tissue sections were stained with hematoxylin and eosin, Masson trichrome, and Movat pentachrome, and were graded for inflammation, tissue substitute degeneration, neointima formation, and calcification. Nonparametric statistical methods were used to test differences

between groups because of small sample size. The eight patients who received PhotoFix pericardium were older (median 10 months vs 10 days, $P < 0.05$) and the material was in situ longer (median 14 vs 2.5 months, $P < 0.05$) compared to the eight who received autologous pericardium. Only three patients received glutaraldehyde preserved bovine pericardium precluding statistical comparison. Inflammation and tissue degeneration were greater in PhotoFix pericardium compared to autologous pericardium but were no more than moderate. Neointima formation and calcification did not differ significantly between the two groups. PhotoFix bovine pericardium is associated with more inflammation and material degeneration but calcification, and neointima formation are similar to autologous pericardium. Although the short-term outcomes are acceptable, calcification and degeneration seen in some cases suggest that long-term outcomes and performance at certain anatomic locations need further study."

3. Backhoff D, Steinmetz M, Sigler M, Schneider H. Formation of multiple conduit aneurysms following Matrix P conduit implantation in a boy with tetralogy of Fallot and pulmonary atresia. Eur J Cardiothorac Surg. 2014; 46(3): 500-2. PubMed link

"We report on a 6-year old boy with tetralogy of Fallot and pulmonary atresia in whom a 16 mm Matrix P® conduit was implanted between the pulmonary artery and the right ventricle at the age of 16 months. Five years later he developed severe stenosis of the distal conduit anastomosis. The notable findings were several aneurysms of the conduit proximal to the distal stenosis within the high-pressure region. The wall of the aneurysms contained xenogeneic conduit tissue without inflammatory or foreign-body response. We believe that aneurysm formation of the conduit was a result of fatigue of the conduit wall under suprasystemic pressure."

4. Bergoend E, Bouissou A, Paoli F, Roullet-Renoleau N, Duchalais A, Neville P. A new technique for interrupted aortic arch repair: the Neville tube. The Ann Thorac Surg. 2010; 90(4): 1375-6. PubMed link

"We have developed a new technique for interrupted aortic arch repair in which the pulmonary artery anterior wall is cut off and tailored so as to re-establish aortic continuity with an autologous tube. We are describing this method herein, with an 8-year follow-up of the first patient."

5. Hopkins RA, Bert AA, Buchholz B, Guarino K, Meyers M. Surgical patch closure of atrial septal defects. Ann Thorac Surg. 2004; 77(6): 2144-2149. PubMed link

"Background: Development of nonsurgical techniques for closure of atrial septal defects (ASD) has prompted reevaluation of current surgical outcomes with an emphasis on less invasive methods.

Methods: This retrospective review is based on a single surgeon's experience between July 1, 1988 and December 21, 2002 with 176 consecutive adult (n = 47) and pediatric (n = 129)

surgeries, in which ASD was the primary anatomical diagnosis to ascertain current optimal methods and outcomes expected for surgical closure. Patch closure with pericardium was used in all cases. Surgical methods encompassed three phases. The first phase was defined by traditional sternotomy; the second phase involved a series of technical modifications to shorten incisions and reduce surgical trauma; the third phase consisted of standardized less invasive techniques based upon age and gender with "bikini line" incisions for adult females, limited median sternotomy for adult males, and mini-median sternotomy for children. All patients underwent echocardiography to assess ASD closure.

Results: There were no deaths. The most frequent perioperative complications were atrial fibrillation (adult 10%, pediatric 1.2%) and post pericardiotomy syndrome (adult 2%, pediatric 4.7%). All patients had secure and complete closure of ASDs with no residual shunts (trivial or otherwise) documented by echocardiography. No less invasive procedures required conversion.

Conclusions: Surgical technique evolved from standard sternotomy to limited access incisions using modified cannulation techniques and incision locations determined by age and gender of the patient without deterioration in outcome quality. Both standard and less invasive surgical methods can achieve secure closure of the septum with biological patches, which are incorporated into the tissue structure of the heart and which are free from materials-related failure modes. Patient satisfaction is enhanced by utilizing the least invasive, least traumatic, and most cosmetically appealing techniques for access and cardiopulmonary bypass."

Photo-oxidation Publications

1. Moore MA. PhotoFix: Unraveling the Mystery. J Long Term Eff Med Implants. 2001; 11(3-4):185-197. PubMed link

   "The use of biological materials in prosthetic heart valves is widespread. Other articles in this issue address many key aspects of these materials. Fixation treatments, biological characteristics, mechanical performance and dysfunction, and the promise of tissue engineering are all discussed. The rest of this issue serves as an introduction to the many aspects of the use of biological materials, whether they are derived from animal sources or are bioassembled on prepared scaffolds. In this article, a particular fixation treatment, dye-mediated photooxidation (PhotoFix®) is discussed. This process yields a material that is biostable, biocompatible, relatively noncalcific, and flexible. It is prepared using a relatively simple method, and the apparent chemical and physical changes in the tissue do not appear to be great. However, the resultant material exhibits dramatically altered biological properties. The mystery of why this simple process produces such dramatic changes is explored here. Despite the title of this article, like many scientific endeavors, our understanding thus far has led to additional questions rather than providing definitive, terminal answers. Thus, "unraveling" the mystery has led to answers as well as some loose ends."

2. Moore MA, Bohachevsky IK, Cheung DT, Boyan BD, Chen WM, Bickers RR, McIlroy BK. Stabilization of pericardial tissue by dye-medicated photooxidation. J Biomed Mater Res. 1994; 28(5): 611-618. PubMed link

   "Bovine pericardial tissue was stabilized through a dye-mediated photooxidation reaction. Shrink temperature analysis of the stabilized tissue indicated a material with similar properties to untreated pericardial tissue and unlike identical tissue treated with glutaraldehyde. Photooxidized tissue was resistant to extraction when compared with untreated tissue or control tissues treated in the absence of light or dye. Photooxidized tissue was also resistant to enzymatic digestion by pepsin and to chemical digestion by cyanogen bromide (CNBr). In contrast, untreated or control treated tissues were readily digested by these reagents. Reduction of photooxidized tissue with beta-mercaptoethanol prior to CNBr digestion partially restored susceptibility of the tissue to CNBr digestion, indicating the photooxidation of methionine residues. Soluble collage derived from bovine pericardium was used as a model compound for the photooxidation reaction. Polycarylamide gel electrophoresis analysis indicated the photooxidation conversion of collagen into higher molecular crosslink formation. Photooxidized tissue was stable to in vivo degradation when compared with control tissue. Results presented here indicate a crosslinked pericardial tissue produced by dye-mediated photooxidation possessing properties of chemical stability, enzymatic stability, in vivo stability, and biochemical integrity suitable for use as a biomaterial."

PhotoFix® | Decellularized Bovine Pericardium

Learn more at: www.CryoLife.com/PhotoFix

PubMed references are courtesy of the National Library of Medicine (NLM).

1655 Roberts Boulevard, NW • Kennesaw, Georgia 30144 • USA
Tel: 770.419.3355 • 800.438.8285 • Fax: 770.590.3753
www.cryolife.com

MLENG1299.000 (08/2018)

CryoLife® Life Restoring Technologies®